

Splints in Horses

Wayne Loch

Department of Animal Sciences

Most people who own or breed horses are familiar with the cannon bone of the horse limb. On each side of the cannon bone is a small bone known as the splint bone. The small splint bones are thin and taper to become a small knob about two-thirds of the way down the cannon bone (Figure 1).

Cause of splints

A ligament, located between the cannon bone and the splint bones, is quite elastic in young horses. As the horse ages, the ligament ossifies; that is, the ligament is replaced by bone and the three bones fuse (Figure 2). During ossification, there may be inflammation and pain. Jumping, running and working a horse during this time produces further irritation.

Splints usually occur in horses 2 to 5 years old. Most

often it is the forelimbs that are affected. Splints rarely occur in the hind legs. In older horses, the splint bones are fused solidly to the cannon bone.

The majority of splint problems occur on the medial side (inside) of the forelimbs. The medial splint bone usually is the one affected because it has a flat surface next to the knee. The lateral (outer) splint bone has a more slanted surface. When the weight is transmitted to these bones, the medial splint bone probably bears more weight than the lateral splint bone. Therefore, the ligament between the medial splint bone and the cannon bone is subjected to more stress than the outer ligament.

Signs of splints

Lameness due to splints is most common in 2-year-old horses undergoing training. The lameness is most obvious while the horse is trotting or working or soon thereafter. Lameness may come and go or be present

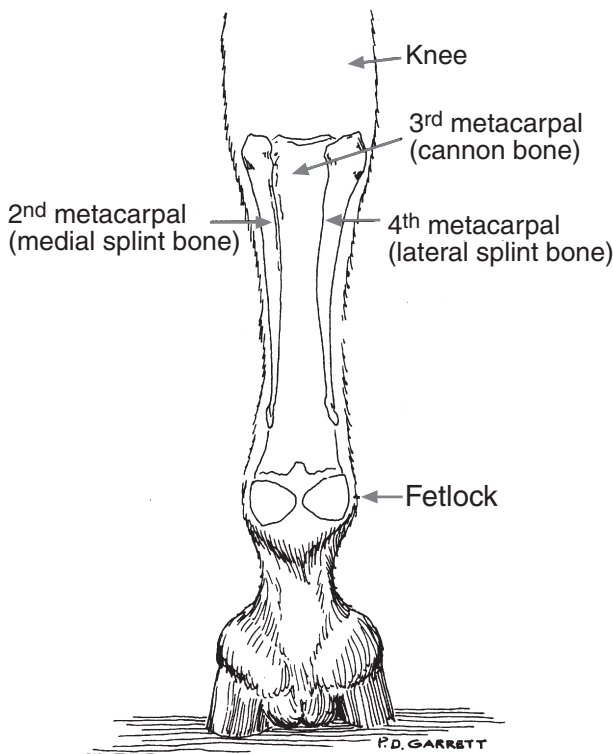


Figure 1. Right forelimb of horse (caudal view).

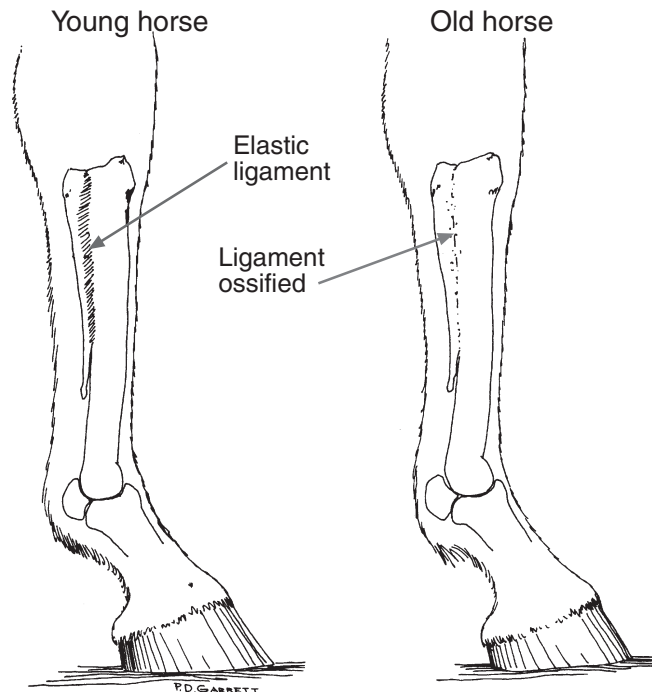


Figure 2. Left forelimb of horses (medial view).

continuously for as long as a year.

If you probe up and down along the cannon bone, the horse will flinch when the portion of the ligament undergoing ossification is touched. A large swelling or a number of smaller swellings due to ossification may occur along the length of the splint bones. After the ligament has ossified, the swelling and soreness usually disappears.

Treatment

Veterinarians use many different methods to treat splint bone conditions. However, the horse should be rested and placed on soft ground for at least 30 days. Veterinarians may use medications to help reduce

inflammation and help prevent excessive bone growth. It is true that splint bone disease may heal without medication and treatment.

The outlook is good for most horses except those in which the bony growth is large and interferes with the knee joint. Sometimes surgery may be helpful in these difficult conditions.

This publication was originally jointly written by Robert C. McClure (professor emeritus) and by Gerald R. Kirk and Phillip D. Garrett. Kirk and Garrett are former faculty members in the Department of Veterinary Anatomy, College of Veterinary Medicine.

